


PATIENT

Mentos Perrin

PRESENTING CLINICAL SIGNS

History: Grade 4 murmur, has progressed since last GPE.

SPECIES

Canine

ECHOCARDIOGRAM FINDINGS

2D, m-mode, color flow and doppler imaging is available. The mitral valve is diffusely thickened with significant prolapse into the left atrial lumen. There is severe eccentric mitral regurgitation present. The MR velocity is normal. There is severe left atrial enlargement. There is moderate left ventricular dilation. Left ventricular systolic function is hyperdynamic. Mild right atrial and ventricular dilation (subjective). Mild thickening of the tricuspid valve with moderate TR. Velocity consistent with normal pulmonary pressures. There is normal systolic flow velocity across the aortic valve. The aortic valve appears trileaflet with normal mobility. Trace AI. The main pulmonary artery is normal in diameter. The pulmonic valve is normal in appearance. No pericardial/pleural effusion or cardiac masses are seen.

BREED

Maltese Mix

SEX

Male Neutered

AGE

7 years

CARDIAC CHART
WEIGHT

10.8lbs

CANINE CARDIAC PARAMETERS	MR VMAX (m/s)	TR VMAX (m/s)	LA/AO (Boon method)	LA/AO (Heart Base; Swe)	FS (%)	EF (%)	EPSS (cm)
NORMAL PARAMETER	4.5-5.5	<2.7	1.3	<1.6	28-40	40-100	<0.6
PATIENT	5.4	2.2	NM	2.0	36	67	NM
CANINE CARDIAC PARAMETERS	HR (BPM)	AV VMAX (m/s)	PV MAX (m/s)	BODY WEIGHT (kg)	LA 2D short axis Base view (cm)	LVIDd Avg; 2D and m-mode short axis (cm)	LVIDs Avg; 2D and m-mode short axis (cm)
NORMAL PARAMETER	50-100	0.7-1.7	0.7-1.6	BELOW	BELOW	BELOW	BELOW
PATIENT	112	1.3	1.0	4.9	2.7	3.5	2.2
*Normal chamber parameters expressed as a mean value (SD)				3	1.27 (5.3)	2.46 (2.46)	1.36 (5.5)
BODY WEIGHT DEPENDENT PARAMETERS				5	1.40 (4.5)	2.74 (5.2)	1.60 (4.7)
*Note: All measurements based upon multi-modal images and methods. An average value is reported.				10	1.50 (3.8)	3.27 (3.5)	2.06 (3.1)
				15	1.83 (2.0)	3.71 (2.4)	2.43 (2.1)
				20	2.02 (1.9)	4.14 (2.2)	2.80 (2.0)
				25	2.18 (2.4)	4.48 (2.9)	3.10 (2.5)
				30	2.33 (3.3)	4.83 (3.9)	3.39 (3.4)
				35	2.48 (4.3)	5.17 (5.0)	3.69 (4.5)
				40	2.62 (5.2)	5.48 (6.1)	3.96 (5.4)
				50	2.88 (7.1)	6.07 (8.3)	4.46 (7.4)

INTERPRETED BY

 Maggie Machen Lamy,
 DVM DACVIM
 (Cardiology)

IMAGING PERFORMED BY

Kelly Reschny, RVT

HOSPITAL NAME

 Chippawa Animal
 Hospital

REFERRING VET

Dr. Dowell

INTERPRETATION OF THE FINDINGS & FURTHER RECOMMENDATIONS

Chronic degenerative valve disease causing severe mitral and moderate tricuspid regurgitation. The LA is significantly dilated indicating a high risk for clinical signs going forward. No additional concurrent issues such as systolic dysfunction are documented.

INVOICE

20868

DATE

9/2/21



PATIENT

Mentos Perrin

SPECIES

Canine

BREED

Maltese Mix

SEX

Male Neutered

AGE

7 years

WEIGHT

10.8lbs

INTERPRETED BY

Maggie Machen Lamy,
DVM DACVIM
(Cardiology)

IMAGING PERFORMED BY

Kelly Reschny, RVT

HOSPITAL NAME

Chippawa Animal
Hospital

REFERRING VET

Dr. Dowell

INVOICE

20868

DATE

9/2/21

With this degree of left heart changes, the risk for spontaneous congestive heart failure is elevated and cardiac supportive medications are indicated as below. A weak diuretic (spironolactone) is included given high risk for decompensation in the future even with no reported symptoms. Assessment of progression in the future will help predict long term outcome, however prognosis is guarded at this stage (late B2). Unfortunately the patient will always be at risk for recurrent CHF, development of arrhythmias/LA tear, syncope and/or sudden death in the future.

Close monitoring for development of associated clinical signs (development of a cough, labored breathing, exercise intolerance or worsening collapse episodes) is recommended. **Monitoring of sleeping breathing rates is recommended as the best way to screen for CHF at home.**

Elective anesthesia is not advised, as there is high risk for complication. If necessary, cardiac protective drug choices (opioid/benzodiazepine premedication, propofol or alfaxalone induction, iso or sevoflurane gas) are recommended. Pre-oxygenate for 5-10 minutes prior to induction and recover in O2 cage. Monitor for arrhythmias, hypotension, and hypoxia both intra and post-operatively and intervene as necessary. Moderate IV fluid restriction is recommended to avoid fluid overload. Avoid heart rate stimulating drugs such as atropine unless clinically indicated.

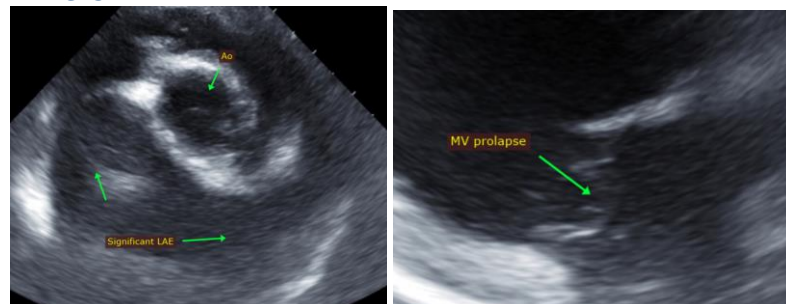
Omega fatty acid supplementation and mild salt restriction may also be of some long term benefit.

Plan: A screening BP is recommended. Administer Pimobendan 0.3mg/kg PO q12h. Institute ACE-I (benazepril or enalapril) 0.5mg/kg PO q12h. Institute spironolactone 1-2mg/kg PO q12h.

Monitor renal values in 1-2 weeks, then every 3-4 months lifelong to ensure tolerance of medications.

A recheck echocardiogram is recommended in 4-6 months to screen for progression, sooner if clinical signs arise.

IMAGES





PATIENT

Mentos Perrin

The information and recommendations provided are based on the images presented by the referring veterinarian. No evaluation can be communicated regarding pathology that was not visible in the image/video clips provided.

SPECIES

Canine

Thank you for this referral. This report was generated using transcription software, and minor dictation errors may be present. If the clinical or image interpretation does not parallel your findings or if I can be of any further assistance please contact me.

BREED

Maltese Mix

Maggie Machen Lamy, DVM
Diplomate of the American College of Veterinary Internal Medicine (Cardiology)
info@sonopath.com

SEX

Male Neutered

AGE

7 years

WEIGHT

10.8lbs

INTERPRETED BY

Maggie Machen Lamy,
DVM DACVIM
(Cardiology)

**IMAGING
PERFORMED BY**

Kelly Reschny, RVT

HOSPITAL NAME

Chippawa Animal
Hospital

REFERRING VET

Dr. Dowell

INVOICE

20868

DATE

9/2/21